

CHAPTER 3

ANATOMY OF THE PALATE AND INSERTION TORQUE OF MINISCREW IMPLANT PLACEMENT

Anatomy of the palate

In maxilla, there are various selectable places for miniscrew implant placement. The two most popular regions are the buccal alveolar region and the palatal region. Miniscrew implants have generally been placed in the buccal area. Buccal miniscrew placement is usually in the interdental region. Common complications are root damage and perforation into the maxillary sinus.¹⁴ The palatal bone a popular placement region with no risk of dental root damage. Moreover, the palate contains attached mucosa and thick cortical bone that may affect the success rate of miniscrew implant placement.^{35,36}

In the hard palate, there are three main bone processes: the premaxilla, the palatine process of the maxilla and the horizontal process of the palatine bone (See Figure 3.1). The premaxilla is the anterior part of the maxilla which is the basal bone for the incisor teeth, and encompasses the anterior nasal spine. In the anterior nasal cavity, the premaxilla projects higher than the maxilla does in the posterior. The incisive foramen is surrounded, anteriorly and laterally, by the premaxilla, and posteriorly by the palatine process of the maxilla.⁵⁰ The palatine process is a thick horizontal process of the maxilla. This area comprises the anterior three-fourths of

the hard palate and connects to the horizontal plate of the palatine bone in the posterior. It is perforated by numerous foramina for the passage of nutrient vessels. The palatine bone is at the posterior part of the nasal cavity between the maxilla and the pterygoid process of the sphenoid. It contributes to the walls of three cavities: the floor and lateral wall of the nasal cavity, the roof of the mouth, and the floor of the orbit. The palatine bone resembles the letter L, and consists of a horizontal and a vertical part and three processes, the pyramidal, orbital and sphenoidal processes.⁵¹ There are three main foramina in the palate: the incisive, greater palatine and lesser palatine foramina. The incisive foramen is a funnel-shaped opening created by the two maxillae joining together. The incisive foramen can be seen in the midline immediately behind the incisor teeth. The greater palatine foramina are at the posterior angle of the hard palate, bilaterally. Behind the greater palatine foramina on each side is the pyramidal process of the palatine bone, perforated by one or more lesser palatine foramina which carry the lesser palatine nerve. The greater and lesser palatine foramina transmit the descending palatine vessels and anterior palatine nerve to the anterior and medial areas of the palate (See Figure 3.2).⁵¹

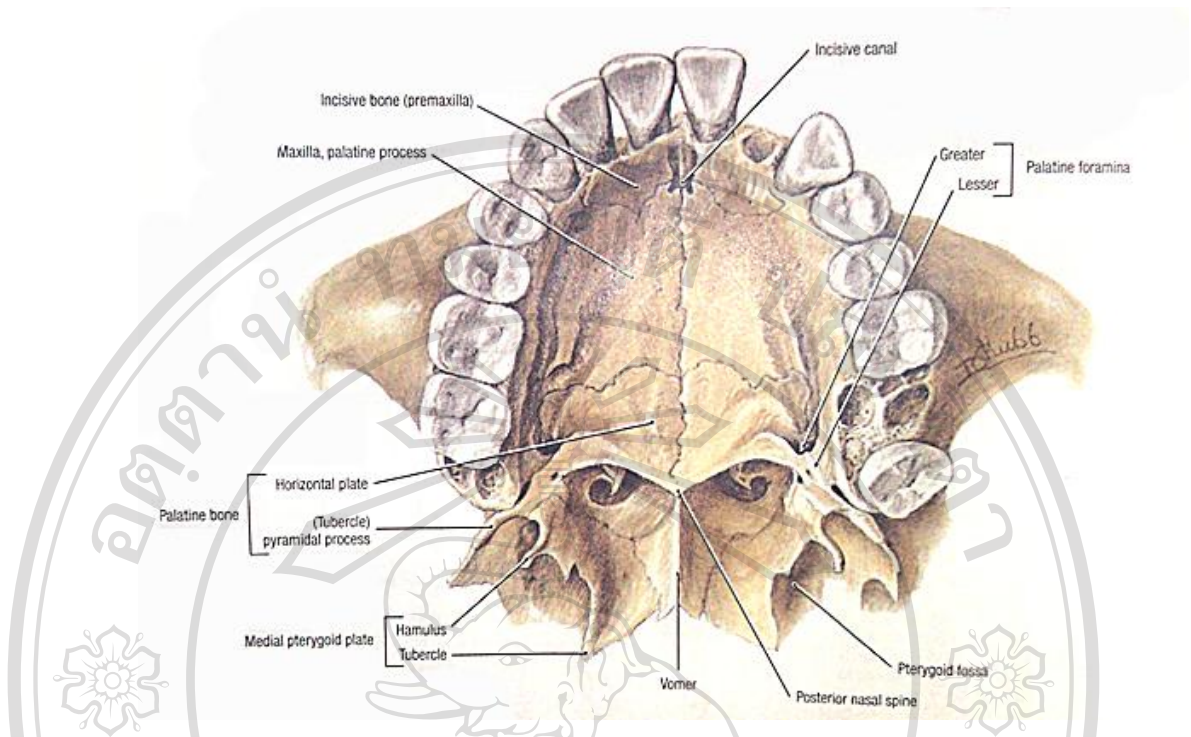


Figure 3.1 Anatomy of the palate.⁵²

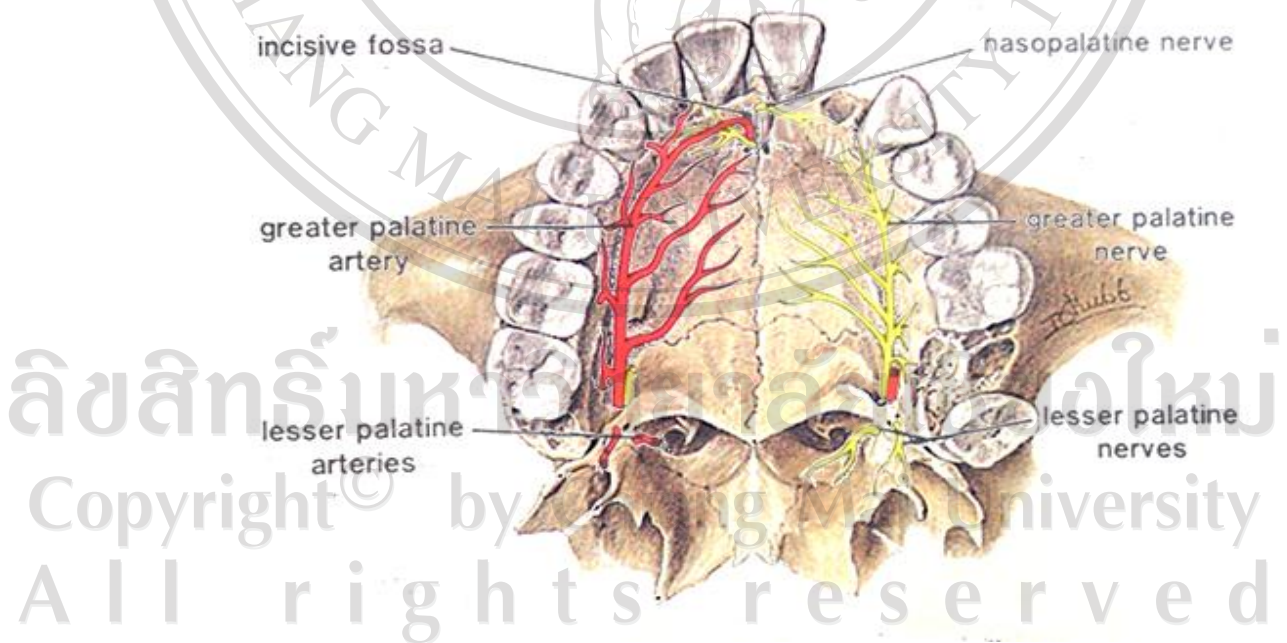


Figure 3.2 Foramina of the palate, blood vessels and nerves.⁵²

In the hard palate, the suture at the midline of the palate is called the midpalatal suture. The midpalatal suture width is about 1.2 to 0.3mm.⁵³ The lateral areas of the midpalatal suture are the parasagittal regions (See Figure 3.3). There are various reviews of the bone in the palate. In terms of the amount of ossification, Knaup et al.⁵⁴ found ossification of 13% of the length of the palatal suture in 44-year-old cadavers and no ossification of the palatal suture in cadavers which were less than 26 years old (See Figure 3.4). In terms of bone quantity, Kang et al.³⁵, in a cone beam computed tomography (CBCT) study, found that the palatal bone height was 6 mm at the midpalatal suture and 3-5 mm in the parasagittal region (See Figure 3.5). This result was similar to that of the histological study of Knaup et al.¹⁵ In terms of bone density, Moon et al., using CBCT, found a uniform density of bone (805-1247 HU) throughout the parasagittal region, at least 3 mm posterior of the incisive foramen and within 5 mm lateral of the midpalatal suture.⁵⁵



Palatal Bone
 ● Anterolateral
 ● Parasagittal Midpalate
 ● Midpalatal Suture (Adults)

Figure 3.3 Midpalatal suture and parasagittal regions.⁵⁶

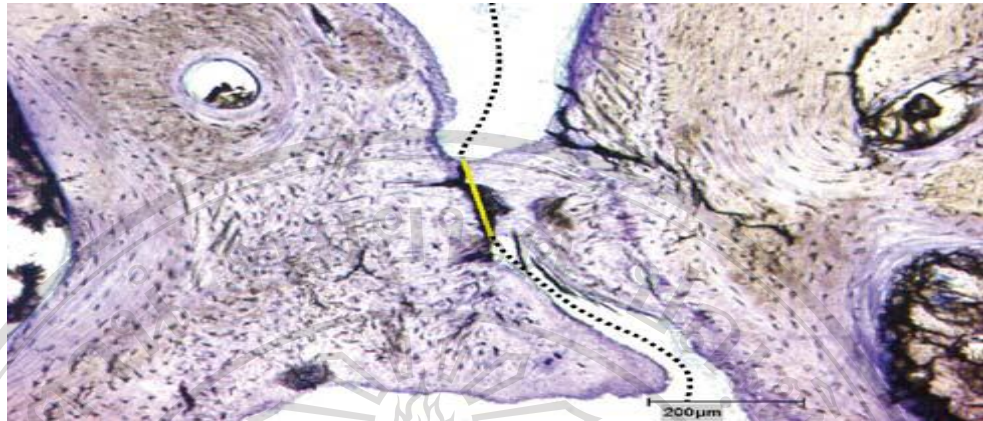


Figure 3.4 Ossification of the midpalatal palatal suture in transversal section through the midpalatal region.⁵⁴

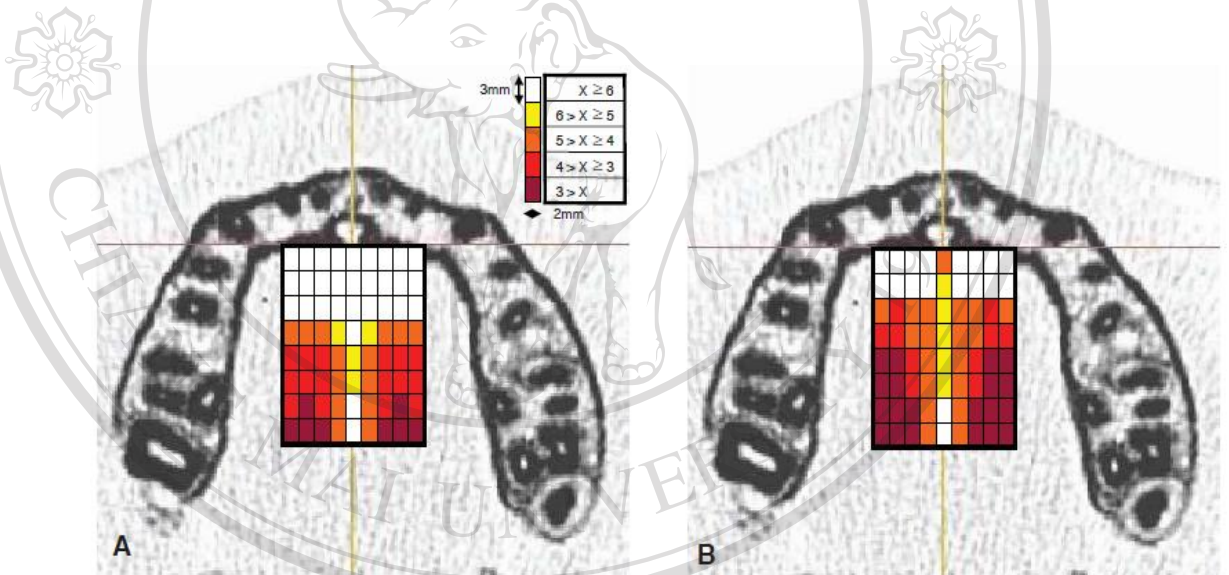


Figure 3.5 Bone thickness of the palate.³⁵

ลิขสิทธิ์มหาวิทยาลัยเชียงใหม่

Copyright © by Chiang Mai University

All rights reserved

The palate consists of attached mucosa and thick cortical bone. Therefore, it is a suitable location for implant placement.

Insertion torque of miniscrew implants

In the past, osseointegrated dental implants were used for stable orthodontic anchorage. However, there were some limitations to the use of such implants, such as a long latent period for osseointegration, invasive surgery, difficulty of removal, the large size of the implants relative to the size of the potential placement sites, and expense.^{33,55,57} Therefore, miniscrew implants were invented, which were less expensive and easier to insert and remove than the original dental implants. In this study, the miniscrew implants were composed of Ti-6Al-4V titanium alloy, whose properties are shown in Figure 3.6.⁵⁸ Miniscrew implants can be inserted into various regions in the jaws.⁵⁹ Nevertheless, lower success rates have been reported with miniscrew implants than with osseointegrated implants.^{9,32,59} Therefore, miniscrew implants were studied to improve the success rate.^{33,57,59} Primary stability is one factor affecting the success of miniscrew implant placement.^{39,59} Primary stability of miniscrew implants can be assessed by measuring the insertion torque of miniscrew implant placement.^{57,59} In 2006, Motoyoshi et al. found a relationship between the insertion torque and the success rate of miniscrew implants.³⁹ Therefore, the insertion torque of miniscrew implants was studied in many articles to improve miniscrew implant stability.^{58,59} However, high insertion torque, which is caused from the compression of the bone, can be the cause of microfracture or ischemia in the surrounding bone. High insertion torque is also a risk of miniscrew implant fracture during insertion.^{39,57,59} In 2006, Park et al. studied the factors associated with the clinical success of miniscrew implants and reported that eight of 227 miniscrew implants fractured during their study.⁶⁰ Miniscrew implant fracture in torsion is

caused by the application of stress which is greater than the screw can withstand (See Figure 3.7).

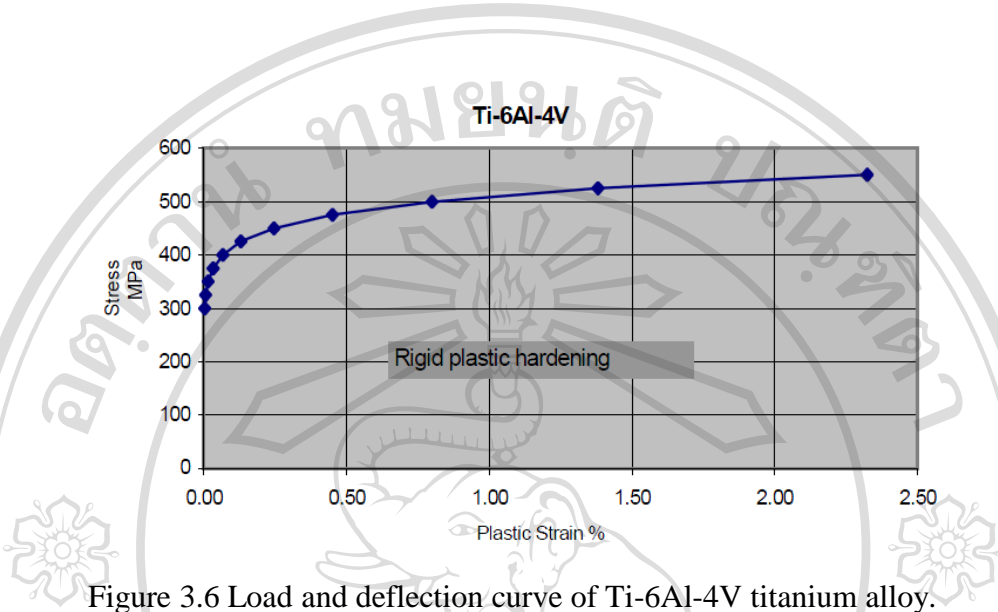


Figure 3.6 Load and deflection curve of Ti-6Al-4V titanium alloy.





Figure 3.7 Insertion torque for miniscrew implant until fracture.⁶¹

Maximum insertion torque is defined as the maximum torque value from the beginning to the end of the insertion of miniscrew implants.^{58,59} Many maximum insertion torque studies of miniscrew implants show various values in different areas of the jaws. Studies focused on the interdental alveolar bone, infrazygoma, hard palate and maxillary tuberosity.^{4,10,11,15,33,34,39,62,63} Insertion torque value depends on the bone quality and quantity.^{39,64} Therefore, different miniscrew placement regions may produce different maximum insertion torque values.^{39,65}



ลิขสิทธิ์มหาวิทยาลัยเชียงใหม่
Copyright© by Chiang Mai University
All rights reserved



ลิขสิทธิ์มหาวิทยาลัยเชียงใหม่

Copyright© by Chiang Mai University

All rights reserved