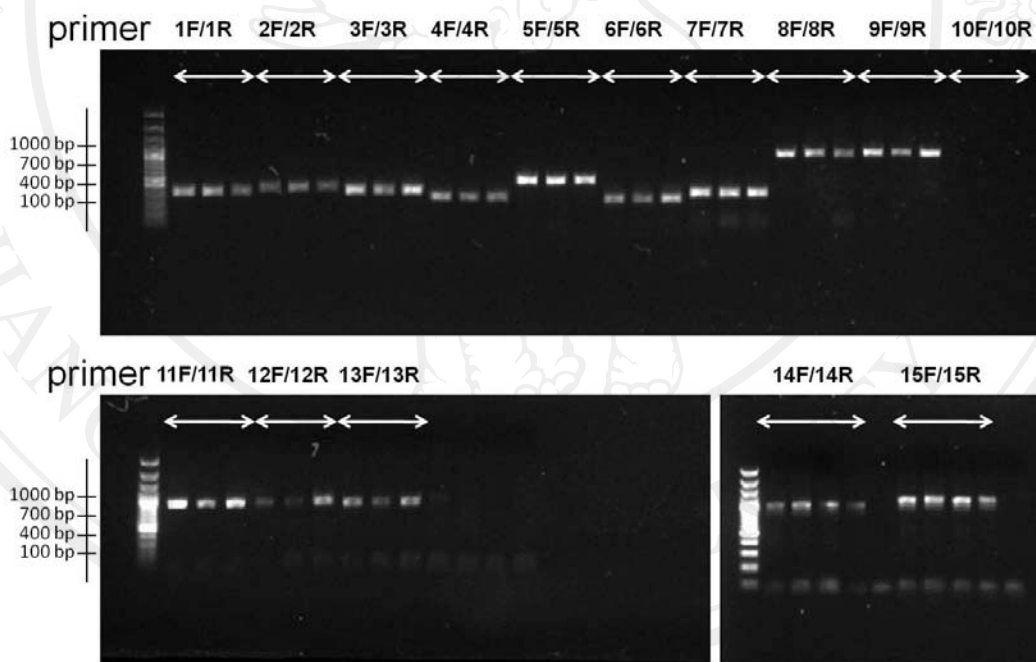


## CHAPTER IV

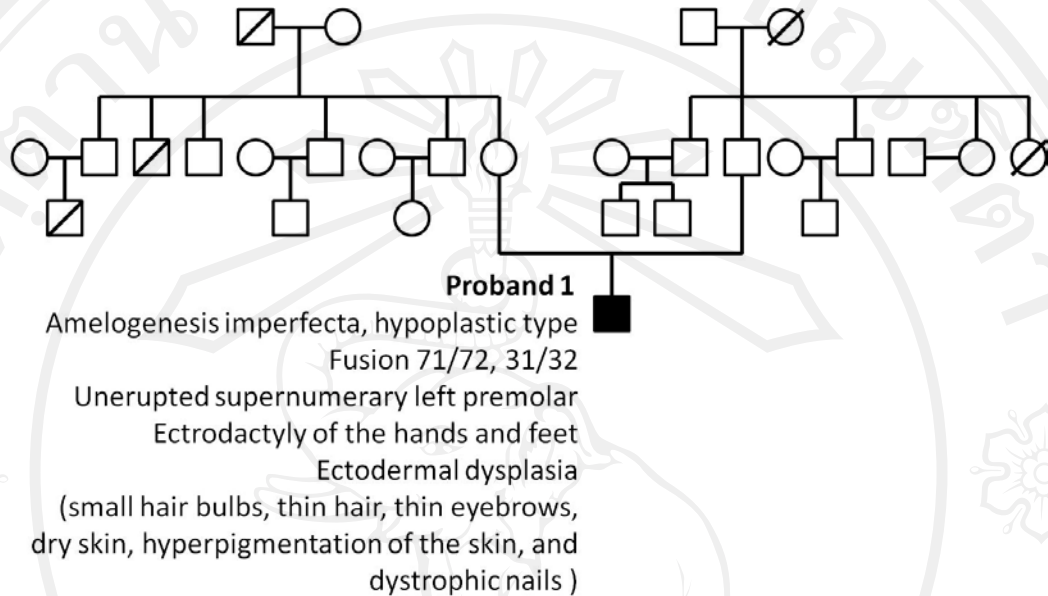
### RESULTS

The PCR products in this study were verified by electrophoresis. Because the author was unable to optimize the conditions for the PCR with primer 10F/10R, this part of exon 10 of *ENAM* was later amplified with the use of two new primer pairs (14F/R and 15F/R), as previously published (Kim et al., 2005a).



**Figure 4.1** Gel electrophoresis of exons 1-10 using different primers.

Six patients with hypoplastic amelogenesis imperfecta were screened for *ENAM* mutations. Among these patients, two were identical twins. Pathogenic mutations were not detected. Nine heterozygous missense variations were detected in three patients. Eight of the variations were recurrent, non-pathogenic, single nucleotide polymorphisms (SNPs). The description of all patients is as follows.

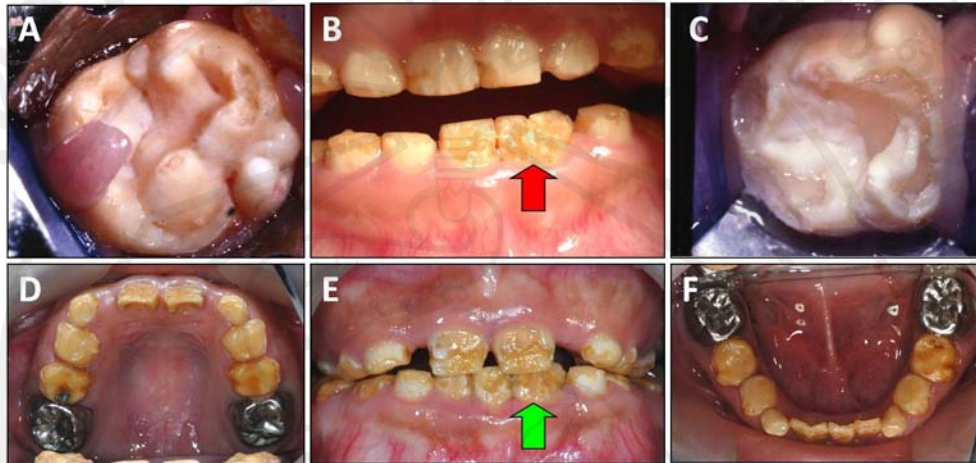
**Family 1****Pedigree**

**Figure 4.2** Pedigree of the family of proband 1 indicating clinical status (“Circle” indicates female, “Squares” indicate males, “Darkened square” indicates the member in whom the phenotypes were found).

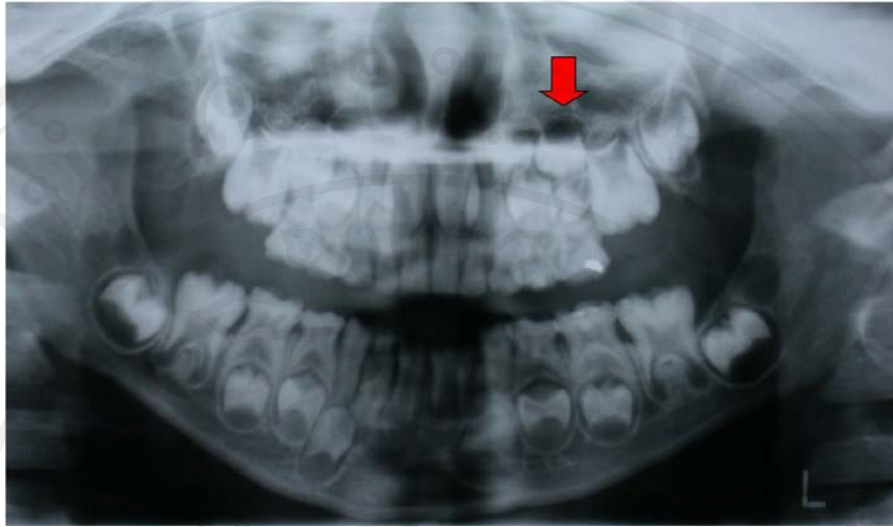
**Clinical evaluations**

Proband 1, a boy, presented with generalized hypoplastic and hypocalcified amelogenesis imperfecta, in both primary and permanent teeth, fusion of the primary mandibular left central and lateral incisors, fusion of the permanent mandibular left central and lateral incisors, unerupted supernumerary maxillary left premolar (Figures 4.2 and 4.3). The affected teeth showed generalized thin, rough-surfaced enamel with yellowish crowns. The radiographic examination showed reduction of radiodensity of enamel compared to the underlying dentine. All permanent first molars were treated with stainless steel crowns. In addition to those features he also had ectrodactyly in both hands and feet, ectodermal dysplasia, including small hair bulbs, brownish, slow-growing and thin hair, thin eyebrows, dry skin, hyperpigmentation of the skin, and dystrophic nails (Figure 4.4). Scanning electron micrography demonstrated hypoplastic hair bulbs, partial loss of hair cuticles, and fraying of the hair shaft (data

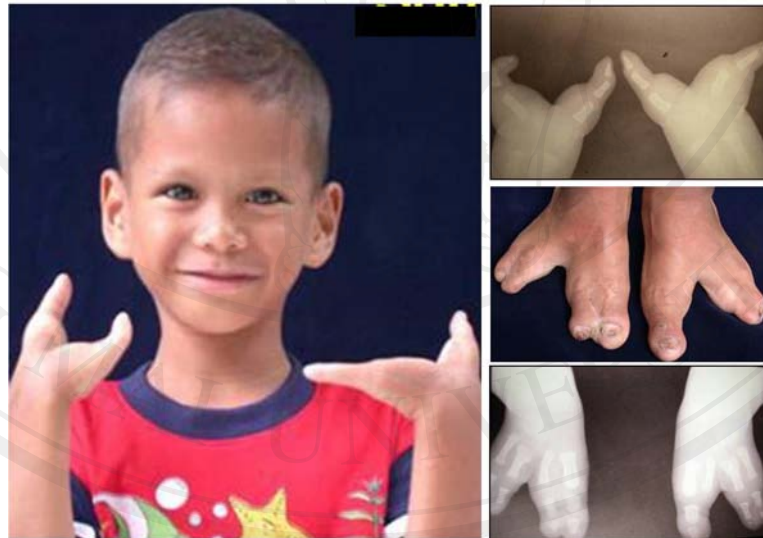not shown). His mother also had ectrodactyly of the hands and feet, normal teeth, ectodermal defects, including brownish and wiry hair, thin eyebrows, dry skin, and hyperpigmentation of the skin (Figure 4.5).



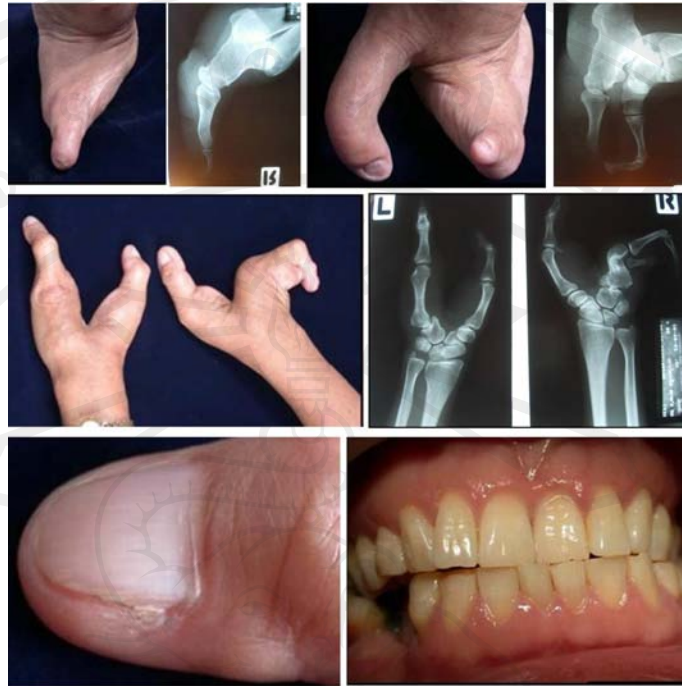**Figure 4.3** Generalized hypoplastic amelogenesis imperfecta in proband 1. (A to C) Oral manifestation of the proband when he was 4 years old shows hypoplastic enamel of the primary dentition. The red arrow indicates the fusion of the primary mandibular left central and lateral incisors. (D to F) Oral manifestation of the proband when he was 8 years old shows generalized hypoplastic enamel, stainless steel crowns on all permanent first molars. The green arrow indicates the fusion of the permanent mandibular left central and lateral incisors.



**Figure 4.4** Panoramic radiograph of proband 1. Red arrow indicates unerupted supernumerary maxillary left premolar. The radiograph shows reduction of radiodensity of enamel compared to the underlying dentine in all teeth.



**Figure 4.5** Clinical and radiographic findings in proband 1. The proband has ectrodactyly in both hands and feet, ectodermal dysplasia including small hair bulbs, brownish, slow growing and thin hair, thin eyebrows, dry skin, hyperpigmentation of the skin, and dystrophic nails.

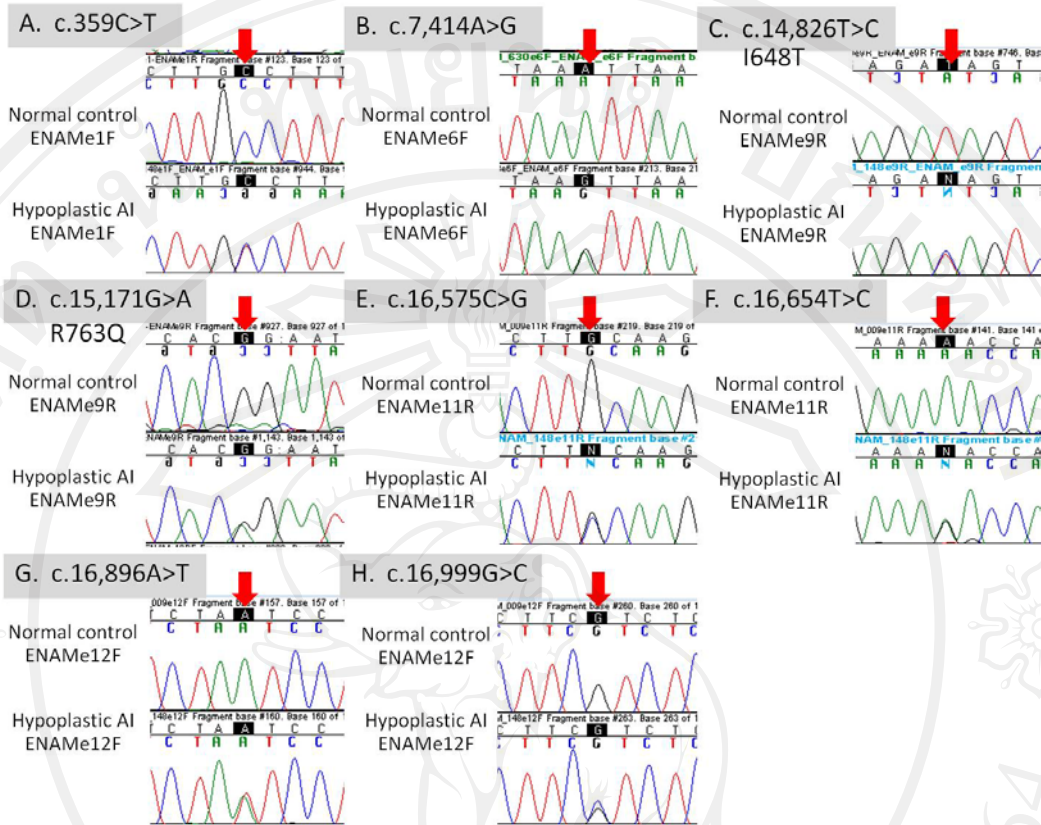


**Figure 4.6** Clinical and radiographic findings in proband 1's mother. Clinical features show ectrodactyly of hands and feet, normal teeth, ectodermal defects, including dry skin, and hyperpigmentation of the skin.

#### Mutation analysis

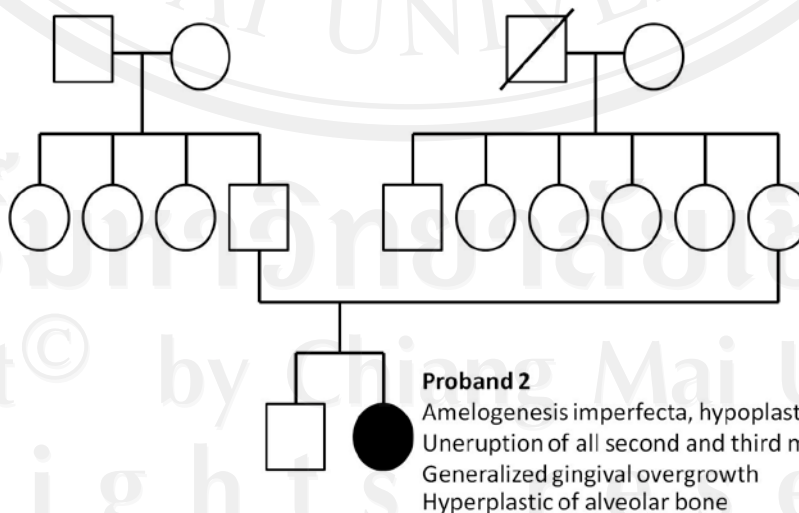
**Table 4.1** *ENAM* single nucleotide polymorphisms (SNPs) in proband 1.

Nucleotide change	Exon/ Intron	Expected amino acid change	dbSNP rs# cluster id
c.-123C>T	Exon 1		rs1993579
c.*63A>G	Intron 8		
c.1,943T>C	Exon 10	I648T	rs7671281
c.2,288G>A	Exon 10	R763Q	rs3796704
c.*265C>G	Intron 10		rs7664896
c.*342T>C	Intron 10		rs7679569
c.*584A>T	Intron 10		rs7695611
c.*687G>C	Intron 10		rs7665492



**Figure 4.7** SNPs in non-coding (A, B, E, F, G and H) and coding (C and D) regions of proband 1 compared with those in a normal sequence.

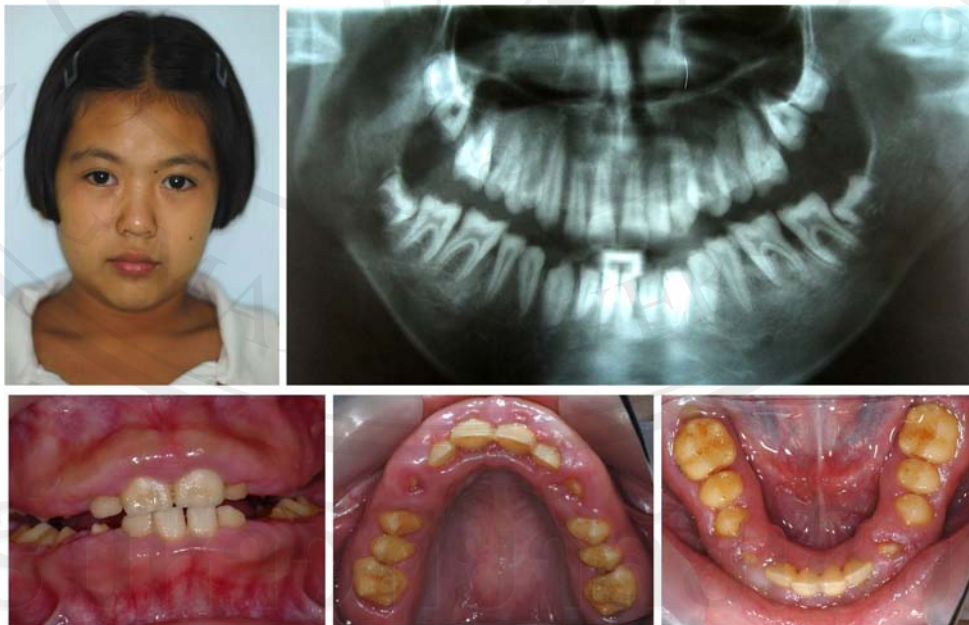**Family 2  
Pedigree**



**Figure 4.8** Pedigree of the family of proband 2 indicating clinical status.

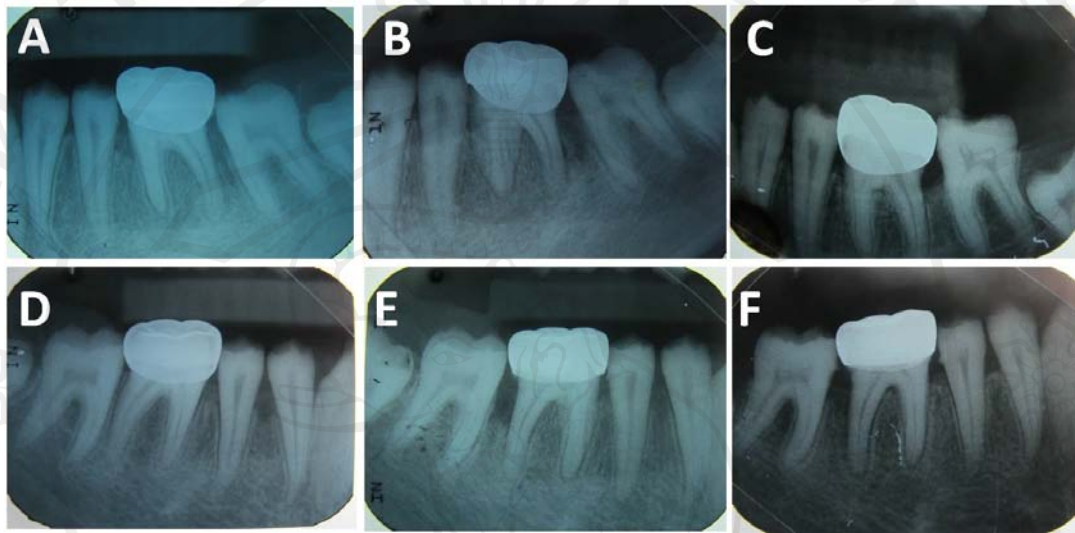
### Clinical evaluations

Clinical examination showed generalized hypoplastic amelogenesis imperfecta of all permanent teeth, generalized gingival overgrowth and hyperplasia of alveolar bone (Figure 4.8). The enamel clinically appeared unusually thin and yellowish due to lack of normal enamel thickness. The proband showed partial eruption of maxillary and mandibular canines. The second and third permanent molars were not erupted. She also had generalized gingival overgrowth. The marginal and interdental gingival enlargement covered the gingival and most of the middle thirds of the erupted teeth. The gingiva appeared pink. The margins of the gingiva were round, with loss of normal gingival scalloping. On palpation, the gingiva was firm in consistency. In order to prevent pathologic attrition, mandibular permanent first molars had been crowned with stainless steel crowns. The panoramic radiographic examination before the teeth were crowned revealed extremely thin to absent enamel with vertical bone loss at the distal root of mandibular left first molar.



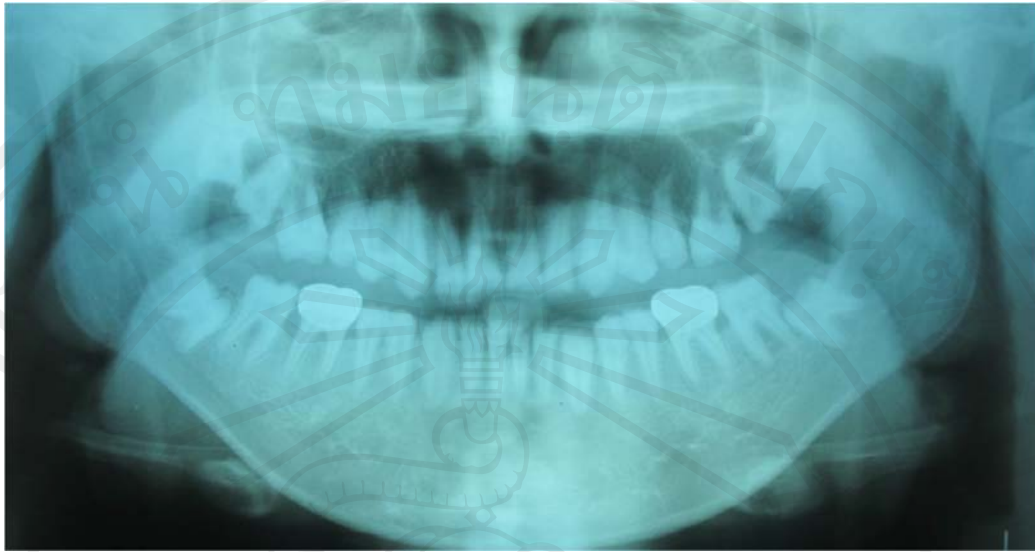**Figure 4.9** Proband 2. Generalized amelogenesis imperfecta, hypoplastic type, with generalized gingival overgrowth. Panoramic radiograph revealed extremely thin to absent enamel. Vertical bone loss was observed at the mandibular first molars. Abnormally wide alveolar process is noted.

The periapical radiographic examination of the mandibular first permanent molars made at a two-year follow-up examination revealed vertical bone loss on both of the mandibular permanent molars which was not evident immediately after the teeth were treated with stainless steel crowns (Figure 4.9 and 4.10).



**Figure 4.10** The periapical radiographic examination of the first permanent mandibular molars in proband 2. (A and D) The periapical radiographs made immediately after the teeth were crowned. (B and E) The periapical radiographs made 6 months after the teeth were crowned, show vertical bone loss at the distal surface of the distal roots. (C and F) The periapical radiographs made two years after the teeth were crowned, show vertical bone loss with a similar alveolar bone level to the periapical radiographs taken 6 months after crowns were placed. The radiographs made two years after the teeth were crowned show alveolar bone healing, especially at the distal surface of the mandibular right first molar.

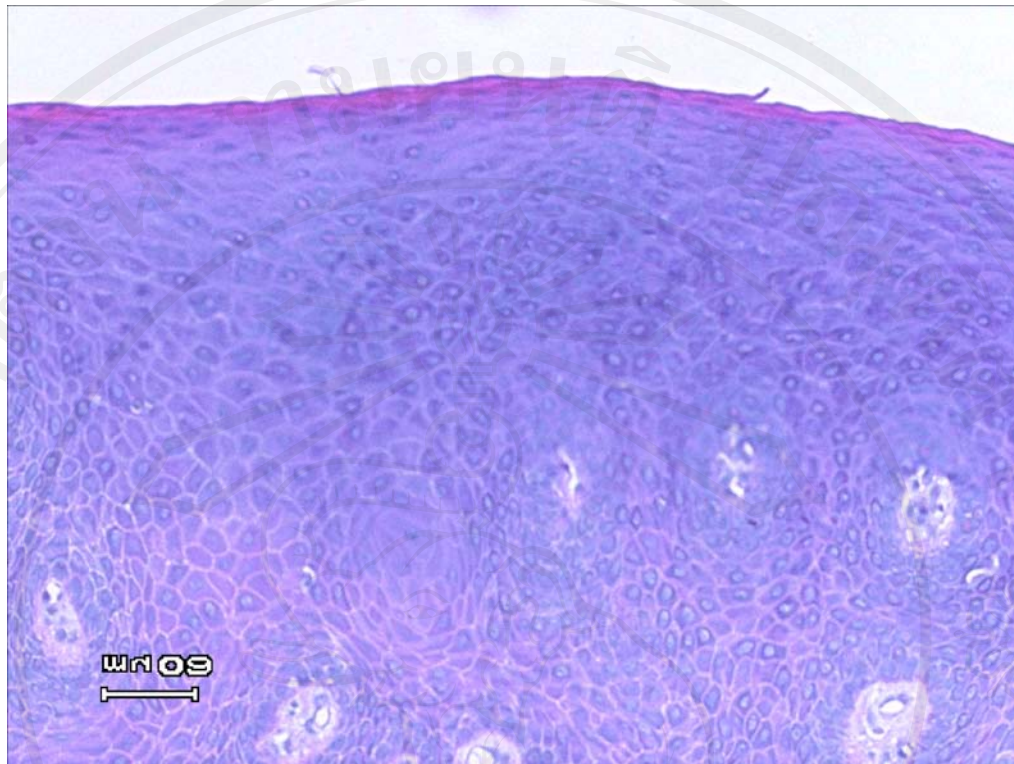




**Figure 4.11** Panoramic radiograph of proband 2, made 2 years after the mandibular first permanent teeth were treated with stainless steel crowns. There is vertical bone loss at the distal of both mandibular permanent molars.

#### **Histopathologic examination**

Microscopic examination of the masticatory gingival cut from the lingual gingival of the mandibular right canine showed acanthotic parakeratinized stratified squamous epithelium with well-vascularized fibrous connective tissue and moderate chronic inflammatory cells infiltration particularly plasma cells. Foci of dystrophic calcification is observed. There is no evidence of neoplasm (Figure 4.11).

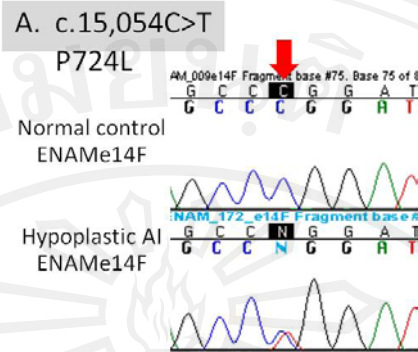


**Figure 4.12** Photomicrograph of the gingival biopsy show stratified squamous epithelium with fibrous connective tissue, dystrophic calcification and chronic inflammatory cells (hematoxylin and eosin, original magnification, x40).

#### Mutation analysis

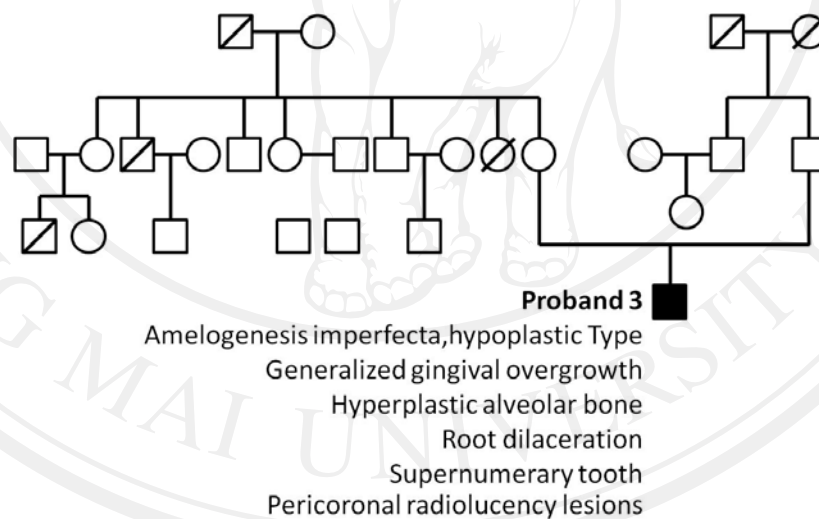
**Table 4.2** *ENAM* single nucleotide polymorphisms (SNPs) in proband 2.

Nucleotide change	Exon/ Intron	Expected amino acid change	dbSNP rs# cluster id
c.2171C>T	Exon 10	P724L	rs3796703



**Figure 4.13** SNPs in a coding region of proband 2 compared with those in a normal sequence.

### Family 3 Pedigree

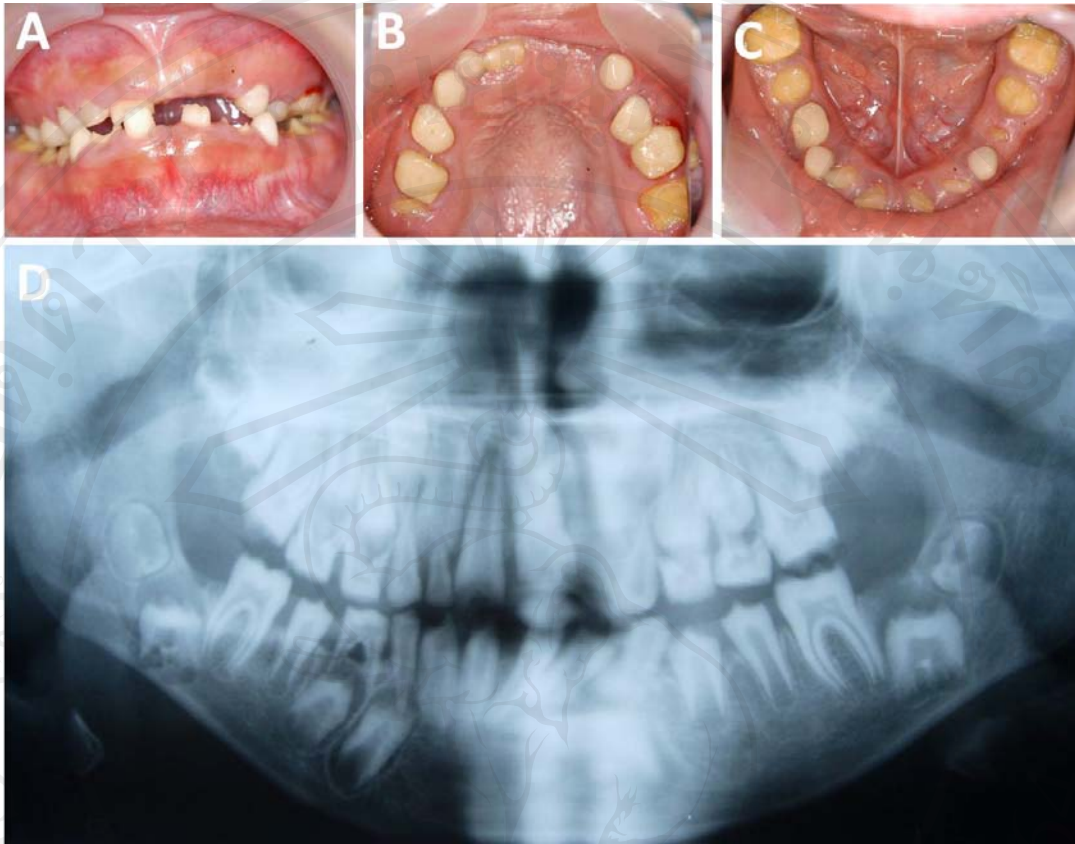


**Figure 4.14** Pedigree of the family of proband 3 indicating clinical status.

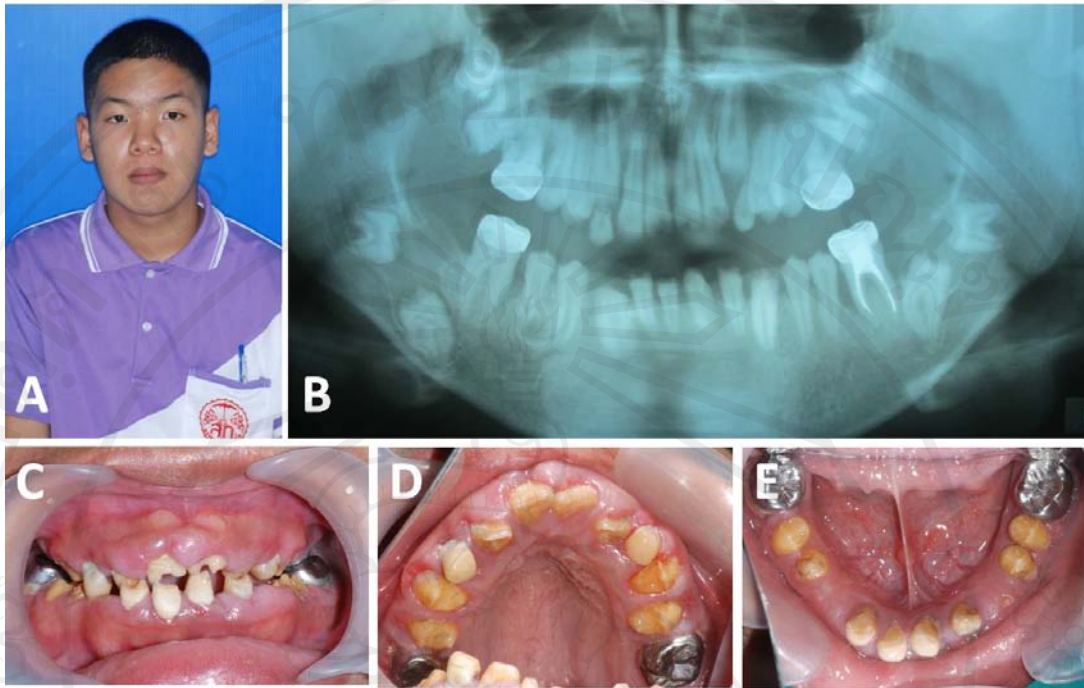
#### Clinical evaluations

Clinical examination of proband 3, a 14-year-old boy, demonstrated amelogenesis imperfecta, hypoplastic type, with generalized gingival overgrowth. Hyperplastic alveolar bone was noted (Figure 4.16 and 4.17). Clinically, the enamel appeared unusually thin and yellowish due to lack of normal enamel thickness. Generalized spacing was observed. All maxillary and mandibular second and third permanent molars were unerupted. Generalized gingival overgrowth was observed

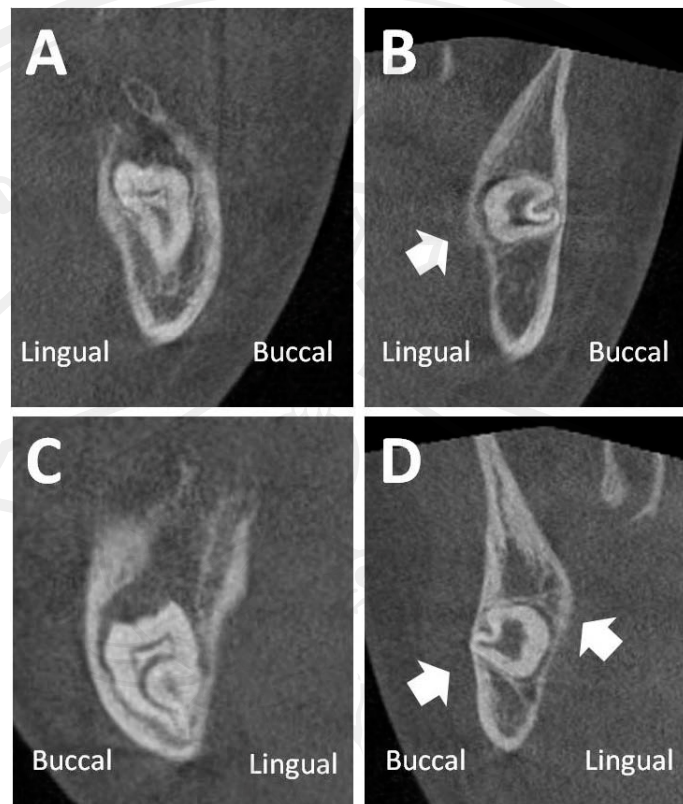
since he was 10 years old. His teeth showed heavy plaque and calculus deposition, especially on the mandibular anterior teeth. Enlargement of the gingiva covered the gingival and most of the middle thirds of all teeth. The gingiva appeared pink. The gingival margin was swollen, with loss of normal gingival scalloping. On palpation, the gingiva was firm in consistency. He had root canal treatment on his mandibular left first molar three months after that tooth was crowned because of the development of a sinus opening, buccal gingival swelling and radiographically evident furcation involvement. All permanent first molars had been treated with stainless steel crowns. The panoramic radiographic examination revealed extremely thin to absent enamel, root dilaceration of the maxillary second molars, supernumerary tooth located between mandibular right premolars, vertical bone loss at both mandibular first molars and large well-define unilocular radiolucent lesions associated with mandibular second and third molars on both sides. Cone beam computed tomography showed impaction and inferiorly displacement of the mandibular second molars, slightly bony expansion associated with horizontal impacted mandibular third molars (Figure 4.18). Wide alveolar process was noted.



**Figure 4.15** (A to C) Amelogenesis imperfecta, hypoplastic type, in mixed dentition, with generalized gingival overgrowth in proband 3 when he was 10 years old. He also had anterior cross bite. (D) The radiographic examination shows extremely thin to absent enamel. Both mandibular second molars are close to the inferior alveolar canals.



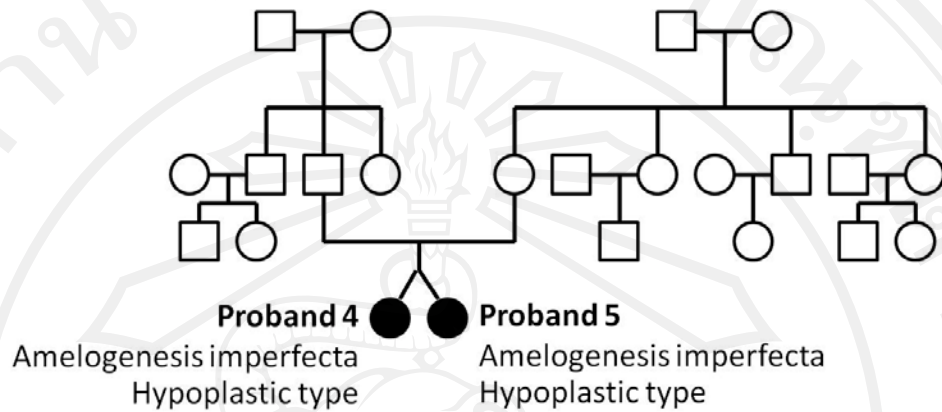
**Figure 4.16** (A) Proband 3 when he was 13 years old. Amelogenesis imperfecta in mixed dentition with generalized gingival overgrowth. (B) The radiographic examination shows extremely thin to absent enamel covering the entire dentition, root dilaceration of the maxillary second molars, supernumerary tooth located between the mandibular right premolars, and vertical bone loss at both mandibular first molars. He had root canal treatment on his mandibular left first molar. All the first permanent molars were crowned. Large, well-defined, unilocular radiolucent lesions associated with the mandibular second and third molars are evident. (C to E) The teeth show heavy plaque and calculus deposition, especially on the mandibular anterior teeth.



**Figure 4.17** (A and C) Cone beam computed tomography shows impaction and inferior displacement of the mandibular second molars, (B and D) slight bony expansion associated with horizontally impacted mandibular third molars as indicated by white arrows.

#### **Mutation analysis**

Pathogenic mutations and SNPs were not detected in this proband.

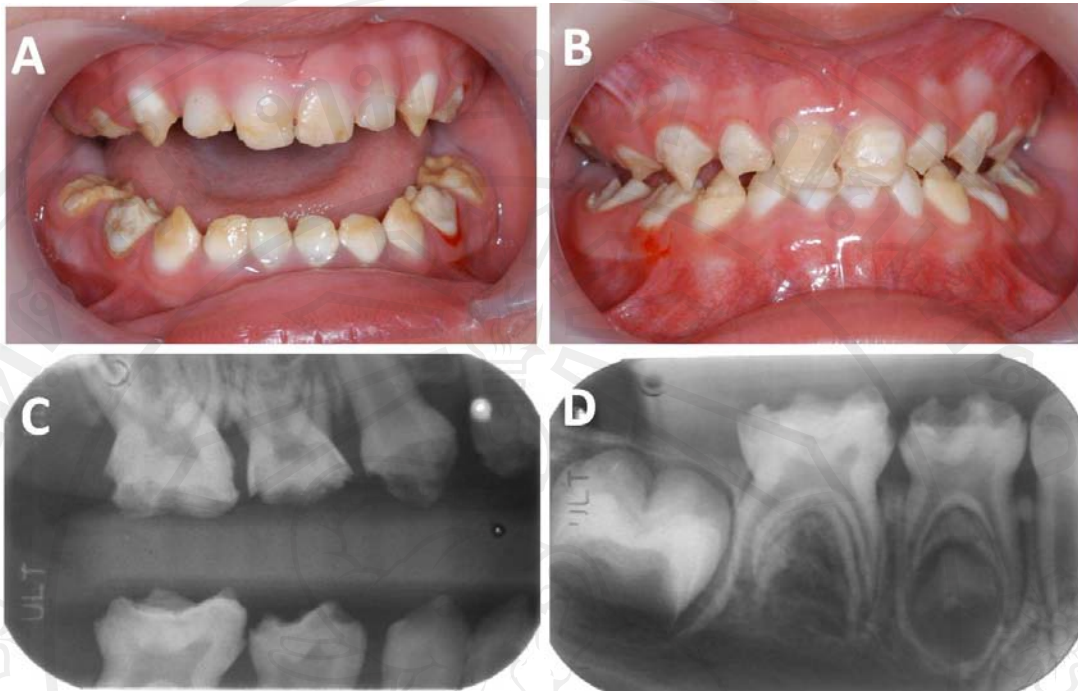
**Family 4****Pedigree**

**Figure 4.18** Pedigree of the family of probands 4 and 5 indicating clinical status.

**Clinical evaluations**

Probands 4 and 5 were given oral and radiographic examinations. These identical twins were affected with generalized hypoplastic and hypocalcified amelogenesis imperfecta in all deciduous teeth (Figure 4.20). Clinically, both probands showed hypoplastic enamel with brown discoloration. In the cervical part of their deciduous teeth, there were several islands of normal-looking enamel. Soft, uncalcified enamel seemed to be worn from masticatory force. The radiographic examination showed reduction in the radiodensity of enamel. The radiograph of the developing permanent tooth showed normal crown morphology with decreased contrast between enamel and dentine.





**Figure 4.19** (A and B) Generalized hypoplastic and hypocalcified amelogenesis imperfecta in probands 4 and 5 respectively. (C and D) The radiographic examinations revealed thin enamel, with reduction of radiodensity of enamel. (D) The radiograph of the developing permanent tooth showed normal crown morphology with decreased contrast between enamel and dentine.

### **Mutation analysis**

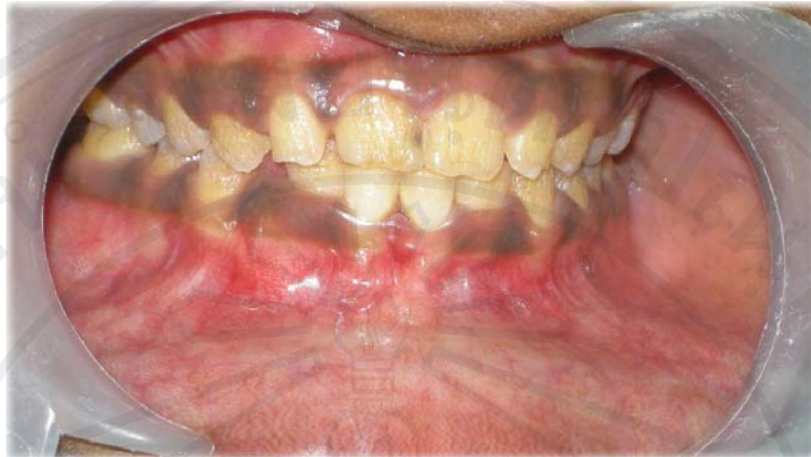Pathogenic mutations and SNPs were not detected.

### **Family 5**

#### **Unknown pedigree**

#### **Clinical evaluations**

An Indian, proband 6, showed generalized thin enamel with yellow-brown discoloration. The labial surfaces of the teeth showed vertical ridges on the enamel, especially on the maxillary central incisors. Chipped incisal edges of the maxillary anterior teeth were observed. It is suspected that his mandibular right permanent canine was missing. Hyperpigmented gingivae were noted (Figure 4.21).



**Figure 4.20** Generalized hypoplastic amelogenesis imperfecta with vertical ridges on labial surfaces of enamel in proband 6.

**Mutation analysis**

Pathogenic mutations and SNPs were not detected.