

CHAPTER 3

MATERIALS AND METHODS

Pre-treatment dental casts, lateral cephalograms, panoramic and periapical radiographs, made using the paralleling technique, of 60 Thai orthodontic patients, 15 males and 45 females, with skeletal Class I (ANB angle = $2^{\circ} \pm 2^{\circ}$, n = 20), skeletal Class II (ANB angle $> 4^{\circ}$, n = 20), and skeletal Class III (ANB angle $< 0^{\circ}$, n = 20) relationships were randomly selected from the orthodontic database in the Department of Orthodontics and Pediatric Dentistry, Faculty of Dentistry, Chiang Mai University. The average age was 18 years with a range of 15 to 28 years.

All radiographs were made in the Department of Radiology, Faculty of Dentistry, Chiang Mai University. Selection criteria included acceptable radiographic quality, fully erupted permanent dentition (except for third molars), no missing teeth (except for third molars), no severe craniofacial disorders (such as a cleft palate) and no history of previous orthodontic treatment. Dental arches with severe crowding or spacing or rotation in the posterior region, abnormal number of teeth, radiographic signs of periodontal disease or periapical lesions, large proximal caries or large proximal fillings, root anomalies such as severe dilacerations and idiopathic root resorption were excluded from the study.

The control group was composed of lateral cephalograms of 59 Thai adults with natural optimal occlusion, normal facial profile (appropriate for race) and soft tissue function. Twenty-eight males and 31 females were chosen. The average age was 20

years with a range of 15 to 29 years. The selection criteria for optimal occlusion were as follows:⁶⁴

- fully erupted permanent dentition except the third molars;
- no missing teeth except the third molars;
- no proximal caries or proximal fillings or full crowns;
- Class I molar and canine relationships with normal occlusal interdigitation;
- 2.0 – 4.0 mm overjet and overbite;
- minimal crowding (less than 3.0 mm) and spacing (less than 1.0 mm);
- no history of previous orthodontic or prosthetic treatment.

The following items were assessed and measured by one examiner:

- 1) Dento-skeletal pattern:
 - lateral cephalometric and mesiodistal tooth angulation measurements
- 2) Interradicular space:
 - angle formed between tooth axes
 - interradicular distance
 - interradicular area
- 3) Other factors: sex, age, severity of malocclusion, presence or absence of the third molar.

Results of the lateral cephalometric and mesiodistal tooth angulation measurements were compared with those of the control group.

3.1 Dento-skeletal pattern factors

Lateral cephalometric and mesiodistal tooth angulation measurements

Lateral cephalometric measurements and mesiodistal tooth angulations on the left side of the jaws, except for central incisors, were assessed on each lateral cephalogram. The measurements were obtained using Smart'n Ceph researcher V9.0 digitizer software (Chiang Mai, Thailand), (Figure 3.1). Results of angular measurements were reported in degrees, linear measurements in millimeters and lower anterior facial height ratio as a percentage.

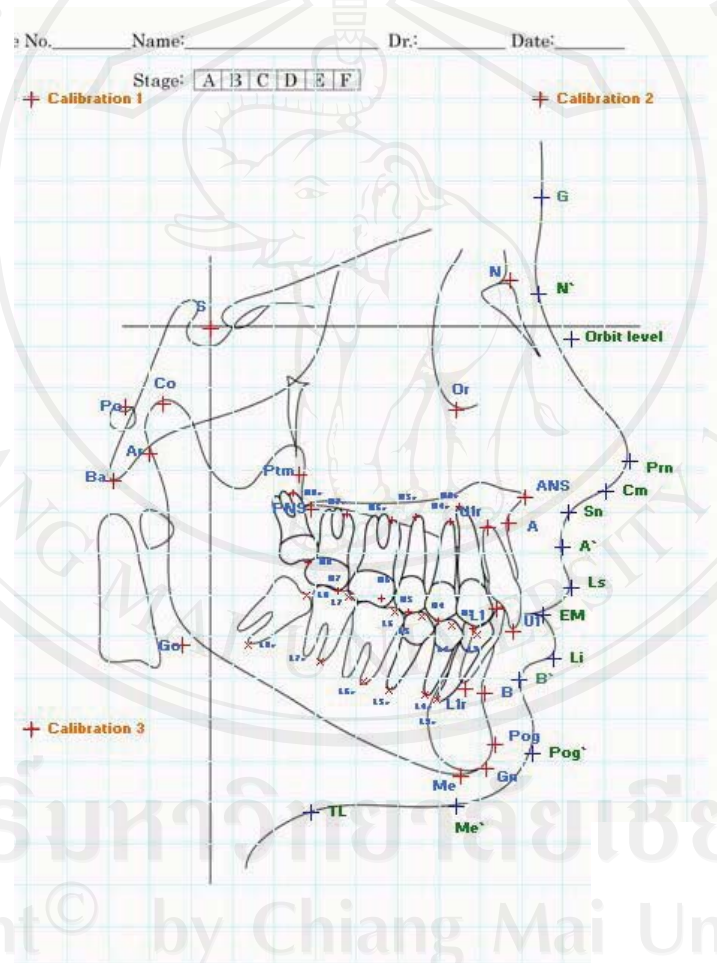


Figure 3.1 Smart'n Ceph researcher V9.0 digitizer software (Chiang Mai, Thailand)

Various cephalometric landmarks, lines, and planes were identified and angular measurements were made.

Cephalometric landmarks

- 1) N (Nasion): The most anterior point of the nasofrontal suture in the median plane.⁶⁵
- 2) S (Sella): A constructed point representing the midpoint of the hypophyseal fossa.⁶⁵
- 3) A (Subspinale): The deepest midline point in the curved bony outline from the base to the alveolar process of the maxilla.⁶⁵
- 4) B (Supramentale): The most anterior part of the mandibular base.⁶⁵ It is the most posterior point in the outer contour of the mandibular alveolar process between the crest of the alveolar ridge (infradentale) and pogonion, in the median plane.⁶⁵
- 5) ANS (Anterior nasal spine): The tip of the bony anterior nasal spine, in the median plane.⁶⁵
- 6) PNS (Posterior nasal spine): A constructed radiographic point, the intersection of a continuation of the anterior wall of the pterygopalatine fossa and the floor of nose.⁶⁵
- 7) Me (Menton): The most inferior point of the outline of the mandibular symphysis in the midsagittal plane.⁶⁵
- 8) Go' (Gonion): Cephalometric gonion is at the intersection of the angle formed by straight lines tangent to the posterior ramus and the inferior border of the mandible.⁶⁶
- 9) U1 (Incisor superius): Tip of the crown of the most anterior maxillary central incisor.⁶⁵
- 10) U1r (Apicale 1): Root apex of the most anterior maxillary central incisor.⁶⁵

- 11) L1 (Incisor inferius): Tip of the crown of the most anterior mandibular central incisor.⁶⁵
- 12) L1r (Apicale $\bar{1}$): Root apex of the most anterior mandibular central incisor.⁶⁵
- 13) U3 and L3 : Cusp tips of the maxillary and the mandibular left canines
- 14) U3r and L3r: Root apices of the maxillary and the mandibular left canines
- 15) U4 and L4 : Cusp tips of the maxillary and the mandibular left first premolars
- 16) U4r and L4r: Root apices of the maxillary and the mandibular left first premolars
- 17) U5 and L5: Cusp tips of the maxillary and the mandibular left second premolars
- 18) U5r and L5r: Root apices of the maxillary and the mandibular left second premolars
- 19) U6 and L6: Mesial cusp tips of the maxillary and the mandibular left first molars
- 20) U6r and L6r: Mesial root apices of the maxillary and the mandibular left first molars
- 21) U7 and L7: Mesial cusp tips of the maxillary and the mandibular left second molars
- 22) U7r and L7r: Mesial root apices of the maxillary and the mandibular left second molars
- 23) U8 and L8: Mesial cusp tips of the maxillary and the mandibular left third molars
- 24) U8r and L8r: Mesial root apices of the maxillary and the mandibular left third molars

Lines and planes

- 1) SN (Sella-Nasion): A straight line drawn between sella and nasion.⁶⁵
- 2) NA (Nasion-Subspinale): A straight line drawn between nasion and subspinale.⁶⁵

- 3) NB (Nasion-Supramentale): A straight line drawn between nasion and supramentale.⁶⁵
- 4) FH (Frankfort horizontal plane): A straight line drawn between porion and orbitale.⁵¹
- 5) ANS-PNS (Palatal plane - PP): A straight line drawn between ANS and PNS.⁶⁵
This plane was used as a reference for the mesiodistal tooth angulation measurements of the maxillary teeth.⁶³
- 6) MP (Mandibular plane): A straight line drawn between Me and Go'.⁶⁵ This plane was used as a reference for the mesiodistal tooth angulation measurements of the mandibular teeth.⁶³
- 7) Tooth long axis: A straight line drawn between tip of the crown or cusp tip and root apex.⁶⁵

Linear measurements

- 1) UAFH (Upper anterior facial height): The distance between N (Nasion) and a straight line drawn through ANS (anterior nasal spine) parallel to the Frankfort horizontal plane.⁶⁵
- 2) LAFH (Lower anterior facial height): The distance between Me (Menton) and a straight line drawn through ANS (anterior nasal spine) parallel to the Frankfort horizontal plane.⁶⁵
- 3) TAFH (Total anterior facial height): The sum of upper and lower anterior facial heights.⁶⁵
- 4) Lower anterior facial height ratio: The proportion of the lower anterior facial height to the total anterior facial height expressed as a percentage.⁶⁵

Angular measurements (Figure 3.2)

- 1) SNA angle: Angle formed by the NA line and the SN line.
- 2) SNB angle: Angle formed by the NB line and the SN line.
- 3) ANB angle: Angle formed by the NA line and the NB line.
- 4) FH-MP angle: The angle between Frankfort horizontal plane and mandibular plane (Me-Go').⁶⁵

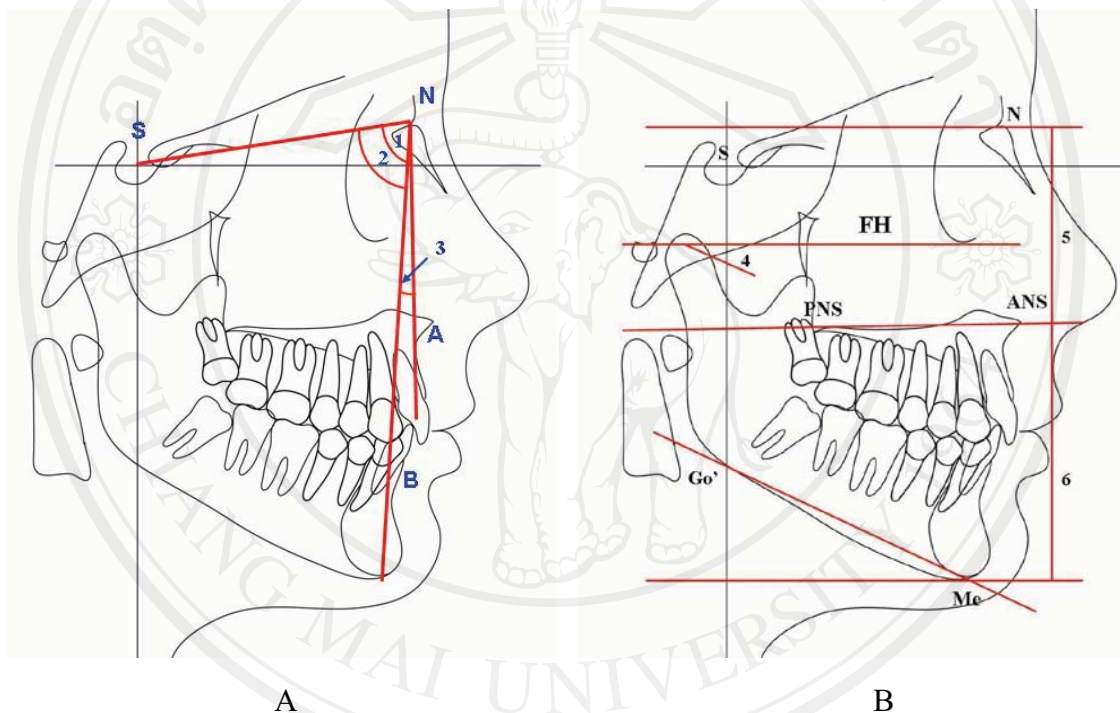


Figure 3.2 Sagittal (A) and vertical skeletal (B) cephalometric measurements: 1, SNA angle; 2, SNB angle; 3, ANB angle; 4, FH-MP angle; 5, UAFH; 6, LAFH

Mesiodistal tooth angulation measurements (Figures 3.3 and 3.4)

- 1) U1 –PP: Angle formed by the maxillary central incisor axis and the palatal plane.⁶⁵
- 2) L1 – MP: Angle formed by the mandibular central incisor axis and the mandibular plane.⁶⁵

- 3) Maxillary canine, premolar, and molar mesiodistal tooth angulations: Angles formed by the tooth long axes and the palatal plane.⁶³
- 4) Mandibular canine, premolar, and molar mesiodistal tooth angulations: Angles formed by the tooth long axes and the mandibular plane.⁶³

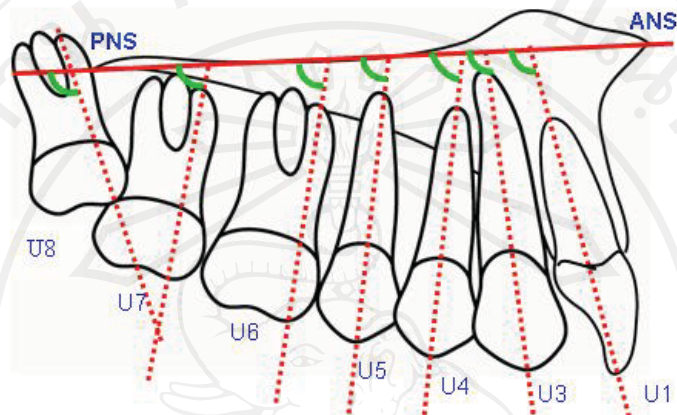


Figure 3.3 Mesiodistal tooth angulation measurements of the maxillary teeth

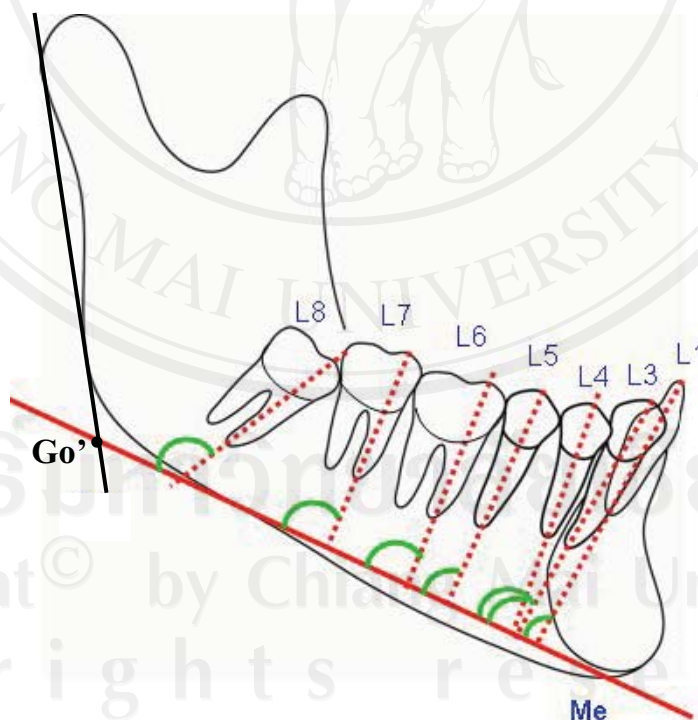


Figure 3.4 Mesiodistal tooth angulation measurements of the mandibular teeth

Effects of different dento-skeletal patterns on the interradicular space were evaluated.

3.2 Interradicular space assessment: angle formed between tooth axes, interradicular distance and interradicular area

Interradicular spaces were defined as interradicular distances and areas. The angles formed between tooth axes were divided into two groups as divergent and convergent tooth root groups. Interradicular distances were defined as mesiodistal distances, measured horizontally at different levels as described below, between the lamina dura of adjacent tooth roots. Interradicular area was defined as the area between the lamina dura of adjacent tooth roots, from the alveolar bone crest to the root apex of each tooth. All periapical radiographs were photographed as digital images, using Nikon D80 digital SLR camera (Sun Jupiter Co., Ltd., Bangkok, Thailand) at fixed magnification, and then transferred to the computer, HP Pavilion a6700z series computer (Hewlett-Packard Development Company, L.P., USA). The interradicular distances at 3, 5, 7, 9, and 11 mm from the alveolar crest, the angle formed between tooth axes, and the area at each interradicular site were measured on the periapical radiograph using custom-made software, Smart'n Ceph V 15.0 (Chiang Mai, Thailand), (Figures 3.5 and 3.6). The measurements were performed in twelve posterior tooth locations: six locations in the maxilla and six locations in the mandible (Figure 3.7).

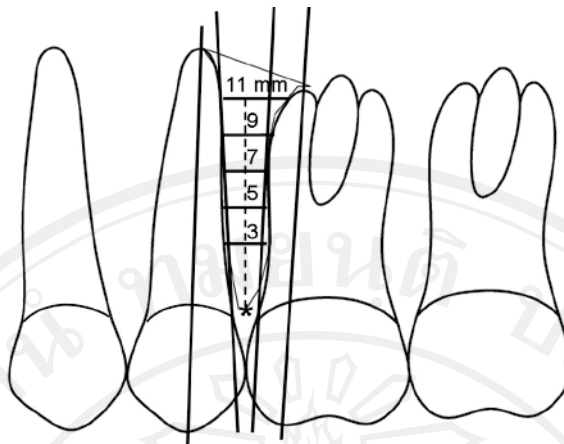


Figure 3.5 Angle formed between tooth axes, interradicular area, and interradicular distance measurements at 3, 5, 7, 9, and 11 mm from the alveolar crest

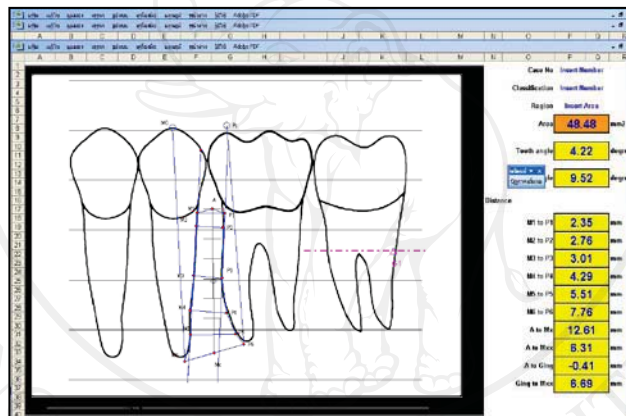


Figure 3.6 The custom-made digitizer software, Smart'n Ceph V 15.0 (Chiang Mai, Thailand)

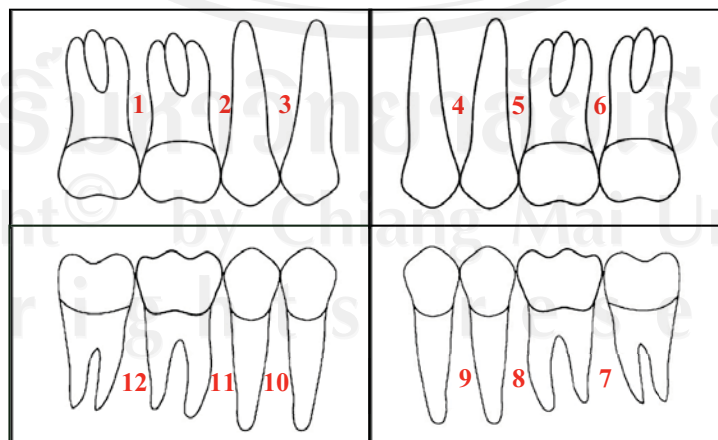


Figure 3.7 A schematic of periapical radiographs indicating locations of measurements.

3.3 Other factors

Effects of other factors, such as sex, age, severity of malocclusion, and presence or absence of the third molar on the interradicular area were also evaluated.

3.3.1 Severity of malocclusion

Severity of malocclusion was assessed on the maxillary and mandibular arches as arch length discrepancies in millimeters. Space analysis was assessed directly on the study models, following the Lundström segmental analysis method, by one examiner.⁶⁷ An electronic digital caliper with an accuracy of 0.01 mm (A&D Company Ltd., Tokyo, Japan), (Figure 3.8) was used to measure the following variables:

- Space available: The space available was calculated by division of the dental arch into four straight line segments, two on each side.⁶⁷ The anterior segments included the central and the lateral incisors. The posterior segments included the canine, the first premolar and the second premolar. Space available was the sum of each segment.
- Space required: The space required was calculated by adding the greatest mesiodistal width of ten maxillary or mandibular teeth from the right second premolar to the left second premolar.⁶⁷ All mesiodistal tooth width measurements were made with the electronic digital caliper perpendicular to the long axis of the tooth with the “jaws” of the caliper in contact with the contact points of the tooth.
- Arch length discrepancy: Arch length discrepancy was the difference between space available and space required.⁶⁷

The effect of the severity of malocclusion on the interradicular area was evaluated.



Figure 3.8 The electronic digital caliper (A&D Company Ltd., Tokyo, Japan)

3.3.2 Presence or absence of the third molar

Maxillary and mandibular third molars were recorded as present or absent based on information from each panoramic radiograph. The effect of the presence or absence of the third molar on the interradicular area was also evaluated.

3.4 Statistical analysis

SPSS version 14.0 for windows was used to analyze the results and the errors of the method.

3.4.1 Statistical assessment of measurement errors

The errors of the method and the reliability of the measurements were tested.

Ten lateral cephalograms, ten periapical radiographs and five pairs of dental casts were randomly selected and re-measured by the same examiner after a 4-week interval. The intra-examiner variation was assessed using a paired Student's t-test ($P < .05$).

Dahlberg's method was used to determine the error between the duplicate determinations, and the coefficient of reliability was also calculated.⁶⁸

3.4.2 Statistical assessment of results

All data were summarized by mean and standard deviation values. One-factor analysis of variance (ANOVA) was used to compare mean lateral cephalometric, mesiodistal tooth angulation, interradicular distance and interradicular area values between the different skeletal patterns. *Post hoc* multiple comparisons were also performed with Tukey's test when ANOVA yielded significant results indicating that there was a difference between the skeletal patterns. The Pearson product-moment correlation coefficients between the interradicular areas and the angles formed between tooth axes, arch length discrepancy, and age were also calculated. The Kruskal-Wallis one-way analysis of variance by ranks was used to compare the number of teeth with convergent and divergent tooth roots between the different skeletal patterns. The Mann-Whitney *U* test was used to compare mean interradicular area values between the present and absent third molar groups, and between sexes. Results were considered statistically significant at $P < 0.05$.